

# Cerebellar Haemangioblastoma: A Case Report

JOANA CHRISTOPHER<sup>1</sup>, J THANKA<sup>2</sup>, B SHOBANA<sup>3</sup>, SANTHANAM RENGARAJAN<sup>4</sup>

CC BY-NC-ND

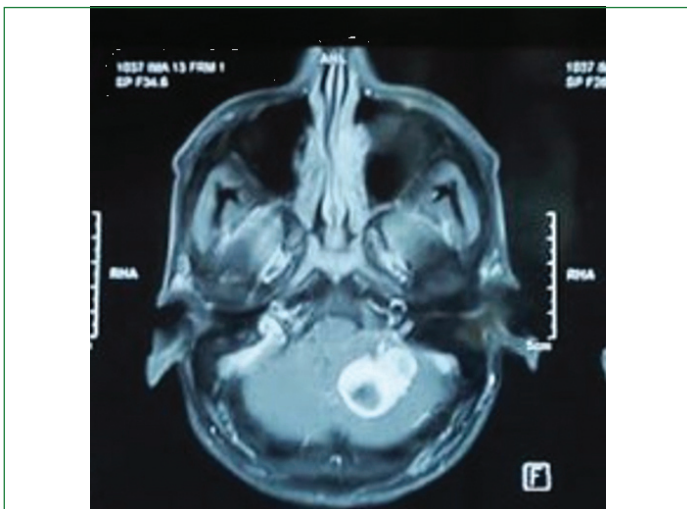
## ABSTRACT

Haemangioblastomas are benign, highly vascular tumours containing neoplastic stromal cells with characteristic immunohistochemical features. They are slow-growing tumours with a solid or cystic pattern of unknown origin and are classified as Grade-I benign tumours. They mostly arise in the cerebellum, medulla and spinal cord and are histologically similar to the vascular lesions in the retina. Haemangioblastomas are the most frequent manifestations of an autosomal-dominant inherited syndrome, von Hippel-Lindau (VHL) disease but can also occur as sporadic non hereditary tumours. Hereby, the current case report is on a 53-year-old male who presented to the tertiary care hospital with a persistent headache for six weeks. Based on just the clinical history and examination, the patient was given a probable diagnosis of either cerebellar haemangioblastoma or cerebellar tumour. Magnetic Resonance Imaging (MRI) was performed, which suggested that the lesion could be a glioma or metastatic deposits from a different tumour. In view of these differentials, the patient underwent tumour excision and decompression via suboccipital craniectomy, and an extraventricular drainage was placed for ease of Cerebrospinal Fluid (CSF) drainage. With the help of histopathological diagnosis, the patient was diagnosed with an apparent sporadic type of cerebellar haemangioblastoma, but this can be confirmed only after detailed genetic screening.

**Keywords:** Benign tumours, Cerebellum, Medulla, Vascular tumours, Von hippel-lindau

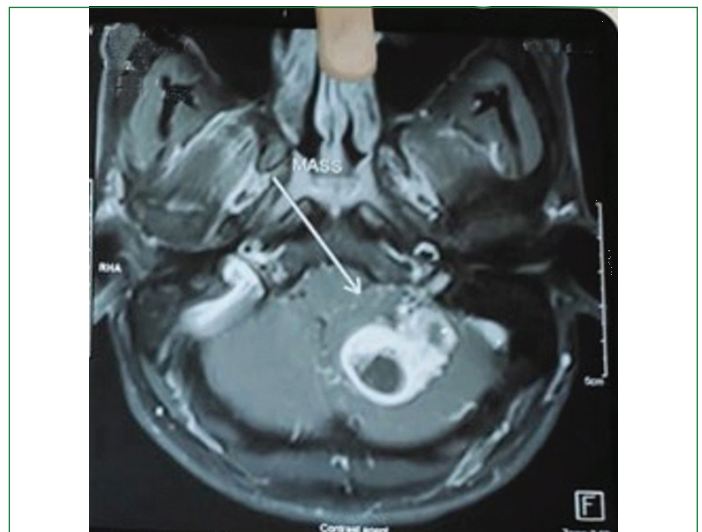
## CASE REPORT

A 53-year-old male patient presented to our hospital with complaint of a persistent headache for the past six weeks. He had no other significant past medical history. Neurological assessment showed bilateral papilledema, nystagmus, and mild tandem ataxia with no motor dysfunction. An MRI of the brain before and following the injection of gadolinium revealed a well-defined lobulated heterogeneous enhancing space-occupying lesion with solid and cystic components seen in the left cerebellar hemisphere, along with adjacent perilesional oedema and mass effect [Table/Fig-1,2]. The lesion measured 3.2×2.6×2.5 cm. There was compression and effacement of the fourth ventricle causing obstructive hydrocephalus, with mild dilatation of the lateral and third ventricles, and periventricular CSF seepage. Multiple T2-weighted Fluid-attenuated Inversion Recovery (T2/FLAIR) hyperintense foci were seen in the bilateral corona radiata.



**[Table/Fig-1]:** Representative brain Magnetic Resonance Imaging (MRI) for haemangioblastoma. T2/FLAIR showing a well-lobulated heterogenous enhancing lesion.

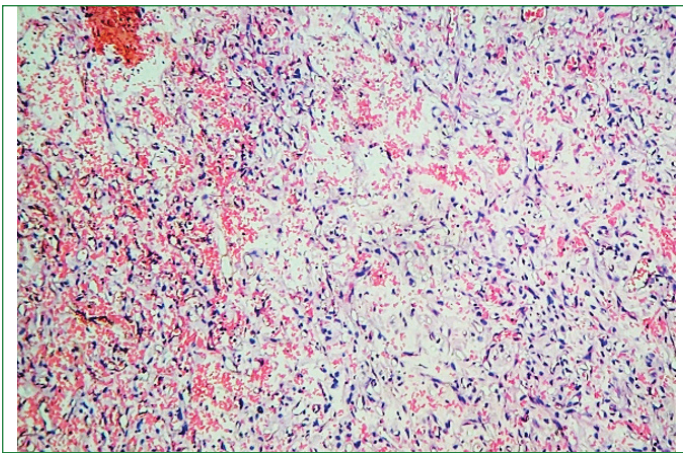
The patient was given a provisional diagnosis of 1) cerebellar haemangioblastoma and 2) left cerebellar tumour based on the above findings. In view of these findings, the patient underwent a suboccipital



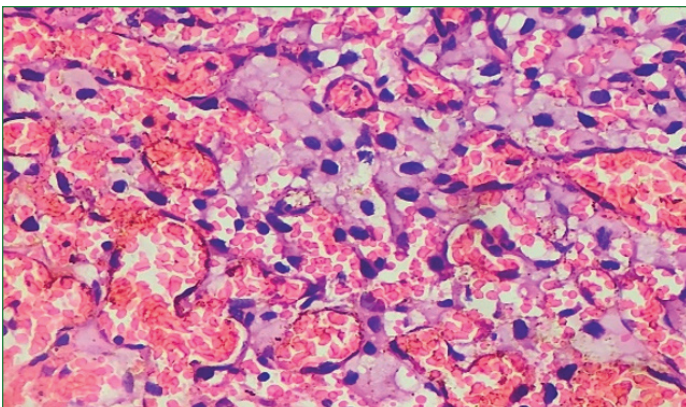
**[Table/Fig-2]:** Representative brain Magnetic Resonance Imaging (MRI) for haemangioblastoma. T2/FLAIR showing space occupying lesion with solid and cystic component.

craniectomy with tumour excision and decompression, resulting in good postoperative results. Macroscopically, the grey-brown mass was well-circumscribed with an irregular external surface and multiple cystic spaces on the cut surface. Microscopically, fragments of tumour tissue with numerous thin-walled blood vessels were observed [Table/Fig-3a,b]. The neoplastic stromal cells were arranged between small blood vessels [Table/Fig-4]. The tumour cells were large, many with foamy cytoplasm. There was mild nuclear pleomorphism, with a few showing degenerative atypia. There was no increase in mitosis, but areas of intratumoral haemorrhage and stromal hyalinisation were seen [Table/Fig-5]. Histopathological examination concluded that it was a case of cerebellar haemangioblastoma.

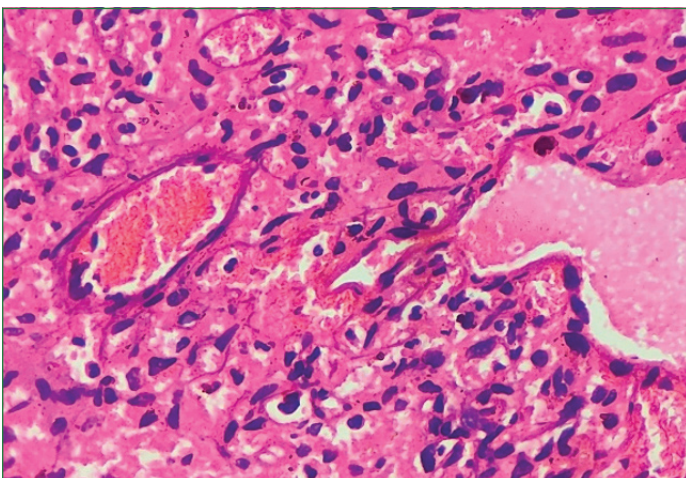
The patient had an uneventful perioperative period and received supportive treatment for wound care, positioning of the head with pillows, and the use of positioning devices to prevent pressure on the cerebrum. Regular neurological assessments were conducted with fall prevention strategies in place. Psychological counseling



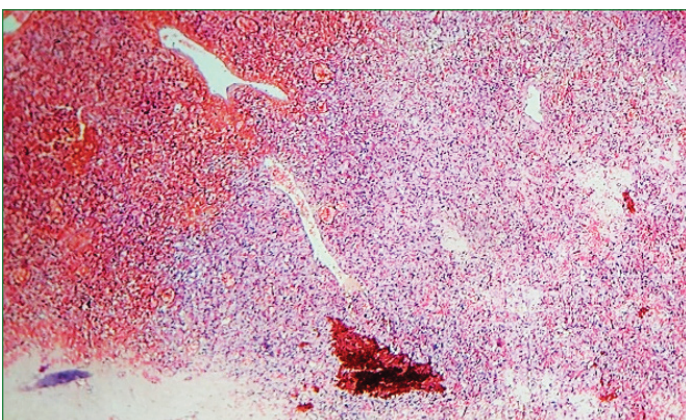
**[Table/Fig-3a]:** Histopathological features of central nervous system hemangioblastoma showing tumour tissue with numerous thin-walled blood vessels (H&E, 10x).



**[Table/Fig-3b]:** Histopathological features of central nervous system haemangioblastoma showing tumour tissue with numerous thin-walled blood vessels (H&E, 40x).



**[Table/Fig-4]:** Microscopic picture showing the neoplastic stromal cells arranged between small blood vessels (H&E, 40x).



**[Table/Fig-5]:** Microscopic picture showing intratumoural haemorrhage and stromal hyalinisation (H&E, 10x).

was also provided during his recovery period. However, the patient was lost to follow-up postsurgery and recovery.

## DISCUSSION

In 1928, Cushing and Bailey suggested the term haemangioblastoma as the tumour was thought to arise from the endothelial cells of the central nervous system [1]. Haemangioblastoma is a benign, highly vascular tumour containing neoplastic stromal cells with characteristic immunohistochemical features. They are slow-growing tumours with a solid or cystic pattern of unknown origin and are classified as Grade-I benign tumours under meningeal tumours in the 5<sup>th</sup> edition of the World Health Organisation (WHO) classification of Central Nervous System (CNS), 2022.

Haemangioblastomas can be found throughout the neuroaxis, but the most common site of occurrence is the cerebellum. They are usually located in the posterior cerebral fossa and are the most common primary intra-axial and infratentorial tumour in adults. However, haemangioblastomas may also be found in the brainstem, spinal cord, cerebrum, retina, peripheral nerves and also outside the CNS. They are rare tumours of the central nervous system and comprises less than 2% of all brain tumours and 7-12% of all infratentorial tumours in adults [2]. They can occur sporadically as isolated tumours with a male-to-female ratio of 1:1 or as tumours with multiple localisations, with a female predominance arising in a younger age group of women in those with von Hippel-Lindau syndrome [3]. They are divided into four types based on their macroscopic description: i) simple cyst; ii) cyst with a mural nodule; (iii) dense tumour; and (iv) solid tumour with small internal cysts [4].

Clinical symptoms of haemangioblastomas include headache, vomiting and ataxia due to the mass effect of the tumour. Increased intracranial pressure and hydrocephalus are also found due to the compression effect of the tumour disabling the proper outflow of CSF. Haemangioblastomas are noted to produce erythropoietin and secondary polycythaemia due to this reason is also noted.

The use of MRI is paramount in the diagnosis of haemangioblastoma, and Haematoxylin and Eosin (H&E) for histopathological assessment is sufficient to conclude the diagnosis. MRI, being the gold standard for diagnosis, reveals contrast-enhancing nodules with cystic structures in between [4]. Angiography can be used when the lesions are small, but the procedure comes with its own risks. Grossly, haemangioblastomas appear as well-circumscribed pseudo-encapsulated masses that are cystic with a mural solid nodule, and in a small number of cases, they can be completely solid. Its cut surface may appear red with yellow and orange variegations due to haemangioblastomas being highly vascular in nature with high lipid content, respectively [5].

Cytologic examination can be useful with techniques like a direct smear or squash preparation. Unfortunately, haemangioblastoma samples frequently result in thick clumps of tissue with squash preparation, making it difficult to make out its cytologic details [6].

In otherwise good smears, the neoplastic cells reveal a characteristic foamy or finely vacuolated cytoplasm with indistinct borders. The nuclei may show mild pleomorphism with hyperchromatic, speckled chromatin, and rarely nuclear grooves. Haemangioblastomas, being highly vascular, frequently demonstrate haemosiderin deposition [6].

Microscopically, two components are seen, which include neoplastic stromal cells and abundant reactive vascular cells composed of: i) endothelial cells lining capillary spaces; ii) pericytes surrounded by the basement membrane; iii) stromal cells or multivacuolated cells and iv) mast cells. The neoplastic stromal cells have round to pleomorphic nuclei with inconspicuous nucleoli and pale vacuolated lipid-laden cytoplasm [3]. The vascular spaces are thin-walled and the tumour is rich in reticulin that separates the vascular cells from the stromal cells. Mitotic figures and cytoplasmic hyaline globules are rarely seen [7,8]. Immunohistochemistry can be used to aid in

the diagnosis; vascular cells stain positive for Cluster Differentiation 31 (CD31), CD34, and reticulin to highlight the blood vessels. The stromal cells stain positive for inhibin alpha, CD56, S100, brachyury, vimentin and aquaporin 1. Electron microscopic studies reveal lipid-laden stromal cells occupying spaces between capillaries [9].

Recognition and accurate diagnosis of haemangioblastoma are essential, as other CNS neoplasms and most tumours associated with VHL disease may pose as mimickers, making its diagnosis challenging [10].

The differential diagnosis for haemangioblastoma are: i) ependymoma; ii) pilocytic astrocytoma; iii) paraganglioma; iv) capillary angioma/haemangioma; v) meningioma and vi) metastatic clear renal cell carcinoma [1]. The diagnosis of haemangioblastoma relies most heavily on histologic and immunophenotypic features, as described by Yoda RA and Cimino PJ [10]. The pathogenesis of haemangioblastoma is not fully understood yet, but according to Favier J and Gimenez-Roqueplo AP, there exists a mechanism that promotes downstream tumorigenesis through the loss of VHL as proposed by the 'pseudohypoxia hypothesis' [11]. Cerebellar haemangioblastoma is one of the most frequent manifestations of autosomal dominant VHL syndrome, but it may also arise sporadically. Patients with VHL disease are more likely to present with multiple haemangioblastomas [12]. The VHL-associated neoplasms include clear cell renal cell carcinoma, head and neck paragangliomas, pheochromocytoma, pancreatic islet cell tumours, cystadenomas of the epididymis and broad ligament, and endolymphatic sac tumours of the inner ear [13].

The majority of familial cases of haemangioblastoma demonstrate germline VHL loss, with a small proportion of sporadic cases showing VHL loss of function. Recent literature by Glasker S et al., Lee JY et al., Shankar GM et al., reveal that 78% of sporadic haemangioblastomas demonstrated VHL alterations [14-16]. In cases without demonstrable VHL alterations, more studies are needed to elucidate the presence or absence of VHL loss or if any other mechanisms are responsible for these sporadic cases [17]. Studies done by Dos Santos AL et al., recommend genetic screening in all patients diagnosed with CNS haemangioblastoma to not miss the diagnosis of VHL in patients with apparently isolated lesions and no evidence of family history [18]. Genetic screening is important, as sporadic haemangioblastomas have an excellent prognosis, but those associated with VHL syndrome have a worse prognosis due to the multiplicity of the tumours, with CNS haemangioblastomas being the primary cause of mortality [19,20]. Surgical excision is the treatment of choice.

## CONCLUSION(S)

In conclusion, the aim of the present case report was to provide a comprehensive overview of the pathological aspect of cerebellar haemangioblastoma. CNS haemangioblastoma is the primary cause of morbidity and mortality in patients with VHL disease. Further studies are needed to elucidate the pathogenesis of this disease, especially in sporadic cases. Through examination of the histological features, immunohistochemical markers, and genetic

alterations, we can gain insight into its cellular origin and molecular characteristics, thereby guiding disease management.

## REFERENCES

- [1] Bakariş S, Mürüvet Y. Cerebellar haemangioblastoma: Four case reports and review of the literature. *Cukurova Medical Journal* [Internet]. 2015;40(1):184-92. Available from: <https://dx.doi.org/10.17826/cutf.73086>.
- [2] Louis DN, Perry A, Wesseling P, Brat DJ, Cree IA, Figarella-Branger D, et al. The 2021 WHO classification of tumors of the central nervous system: A summary. *Neuro Oncol*. 2021;23(8):1231-51.
- [3] Kuharic M, Jankovic D, Splavski B, Boop FA, Arnautovic KI. Haemangioblastomas of the posterior cranial Fossa in adults: Demographics, clinical, morphologic, pathologic, surgical features, and outcomes. A systematic review. *World Neurosurg*. 2018;110:e1049-62.
- [4] Lahkim M, Andour H, Laamrani FZ, Allaoui M, Saouab R, El Fenni J, et al. Cerebellar haemangioblastoma: Case report with review of the literature. *Radiol Case Rep* [Internet]. 2021;16(10):3109-12. Available from: <https://dx.doi.org/10.1016/j.radcr.2021.07.027>.
- [5] Ganeshan D, Menias CO, Pickhardt PJ, Sandrasegaran K, Lubner MG, Ramalingam P, et al. Tumours in von Hippel-Lindau syndrome: From head to toe-comprehensive state-of-the-art review. *Radiographics*. 2018;38(3):849-66.
- [6] Commins DL, Hinton DR. Cytologic features of haemangioblastoma: Comparison with meningioma, anaplastic astrocytoma and renal cell carcinoma. *Acta cytologica*. 1998;42(5):1104-10.
- [7] Wang X, Haines III GK, Mehrotra M, Houldsworth J, Si Q. Primary haemangioblastoma of the kidney with molecular analyses by next generation sequencing: A case report and review of the literature. *Diagnostic Pathology*. 2022;17(1):34.
- [8] Shin Y, Kim S, Lee HW, Bang H, Suh YL. Supratentorial haemangioblastoma with unusual features. *Korean Journal of Pathology*. 2014;48(6):462.
- [9] Capper D, Stichel D, Sahm F, Jones DT, Schrimpf D, Sill M, et al. Practical implementation of DNA methylation and copy-number-based CNS tumour diagnostics: The Heidelberg experience. *Acta Neuropathologica*. 2018;136(2):181-210.
- [10] Yoda RA, Cimino PJ. Neuropathologic features of central nervous system haemangioblastoma. *J Pathol Transl Med*. 2022;56(3):115-25.
- [11] Favier J, Gimenez-Roqueplo AP. Pheochromocytomas: The (pseudo)-hypoxia hypothesis. *Best Pract Res Clin Endocrinol Metab*. 2010;24(6):957-68.
- [12] Conway JE, Chou D, Clatterbuck RE, Brem H, Long DM, Rigamonti D. Haemangioblastomas of the central nervous system in von Hippel-Lindau syndrome and sporadic disease. *Neurosurgery*. 2001;48(1):55-63.
- [13] Maher ER, Neumann HP, Richard S. von Hippel-Lindau disease: A clinical and scientific review. *European Journal of Human Genetics*. 2011;19(6):617-23.
- [14] Glasker S, Bender BU, Apel TV, van VV, Mulligan LM, Zentner J, et al. Reconsideration of biallelic inactivation of the VHL tumour suppressor gene in haemangioblastomas of the central nervous system. *J Neurol Neurosurg Psychiatry*. 2001;70(5):644-48.
- [15] Lee JY, Dong SM, Park WS, Yoo NJ, Kim CS, Jang JJ, et al. Loss of heterozygosity and somatic mutations of the VHL tumour suppressor gene in sporadic cerebellar haemangioblastomas. *Cancer Research*. 1998;58(3):504-08.
- [16] Shankar GM, Taylor-Weiner A, Lelic N, Jones RT, Kim JC, Francis JM, et al. Sporadic haemangioblastomas are characterized by cryptic VHL inactivation. *Acta Neuropathol Commun*. 2014;2:167.
- [17] Takayanagi S, Mukasa A, Tanaka S, Nomura M, Omata M, Yanagisawa S, et al. Differences in genetic and epigenetic alterations between von Hippel-Lindau disease-related and sporadic haemangioblastomas of the central nervous system. *Neuro-Oncology*. 2017;19(9):1228-36.
- [18] Dos Santos AL, Trevas S, Rosado ML, Santos A. A challenge in diagnosis of cerebellar haemangioblastoma. *Cureus*. 2022;14(1):e21713.
- [19] Miyagami M, Katayama Y, Nakamura S. Clinicopathological study of vascular endothelial growth factor (VEGF), p53, and proliferative potential in familial von Hippel-Lindau disease and sporadic haemangioblastomas. *Brain Tumour Pathology*. 2000;17:111-20.
- [20] Binderup ML, Jensen AM, Budtz-Jorgensen E, Bisgaard ML. Survival and causes of death in patients with von Hippel-Lindau disease. *J Med Genet*. 2017;54(1):11-18.

### PARTICULARS OF CONTRIBUTORS:

1. Postgraduate, Department of Pathology, Sree Balaji Medical College and Hospital, Chennai, Tamil Nadu, India.
2. Director and Professor, Department of Pathology, Sree Balaji Medical College and Hospital, Chennai, Tamil Nadu, India.
3. Associate Professor, Department of Pathology, Sree Balaji Medical College and Hospital, Chennai, Tamil Nadu, India.
4. Professor, Department of Neurosurgery, Sree Balaji Medical College and Hospital, Chennai, Tamil Nadu, India.

### NAME, ADDRESS, E-MAIL ID OF THE CORRESPONDING AUTHOR:

J Thanka,  
CLC Works Road, Shankar Nagar, Chromepet, Chennai-600044, Tamil Nadu, India.  
E-mail: [thanka7paul@gmail.com](mailto:thanka7paul@gmail.com)

### AUTHOR DECLARATION:

- Financial or Other Competing Interests: None
- Was informed consent obtained from the subjects involved in the study? No
- For any images presented appropriate consent has been obtained from the subjects. Yes

### PLAGIARISM CHECKING METHODS: [Jain H et al.]

- Plagiarism X-checker: Apr 02, 2024
- Manual Googling: May 11, 2024
- iThenticate Software: May 20, 2024 (14%)

### ETYMOLOGY: Author Origin

EMENDATIONS: 6

Date of Submission: **Apr 02, 2024**  
Date of Peer Review: **Apr 27, 2024**  
Date of Acceptance: **May 21, 2024**  
Date of Publishing: **Jul 01, 2024**